

Smile Makeover using a Minimally Invasive Multidisciplinary Approach

DR. NADEEM YOUNIS, BURNLEY/LANCASHIRE

APRIL 2018

Assessment

In this case, a female patient in her late 30s presented to the practice with moderate upper anterior crowding, a discoloured upper left central incisor and defective composite restorations in the upper central incisors (Fig. 1). Unhappy with the overall aesthetics of her smile, the patient was keen to undergo a smile makeover using a minimally invasive treatment pathway.

To help ensure the patient made an informed decision, several treatment options were discussed including orthodontics, tooth whitening, composite resin restorations and ceramic veneers. After consultation, the patient chose the more conservative option of composite resto-

rations, following comprehensive orthodontics and tooth whitening. By opting for the less intrusive – and also more cost effective – process of alignment, bleaching and bonding, all of the patient's concerns were addressed safely and effectively.

Alignment and bleaching

The upper anterior crowding was resolved by using a removable appliance to expand the arch followed by a conventional fixed appliance to align the anterior labial segment. The orthodontic treatment took approximately 12 months (Fig. 2 and 3). Once the anterior crowding had been remedied using conventional fixed appliances, tooth whitening was carried out on the upper left inci-

sor using the inside/outside technique to correct the internal discolouration. For this, an Essix retainer was used with 16% carbide peroxide gel, with instructions given to wear the tray at all times for three to five days changing the whitening gel twice a day during this time (Fig. 4 and 5).

After five days of whitening, the access cavity of the upper left central incisor was sealed and the patient was instructed to wear the tray at night-time only using the whitening gel to whiten the rest of the upper arch (Fig. 6 and 7). Once a satisfactory shade was obtained, there was a pause in treatment for three weeks prior to restoring the central incisors with direct composite resin restorations, to allow the oxygen to dissipate

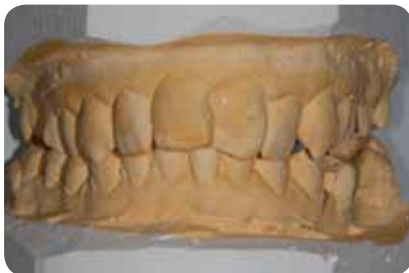

Fig. 1: Patient's preop occlusion

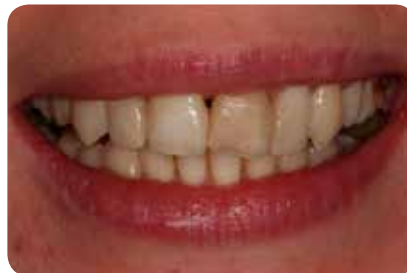

Fig. 2: Pre-op smile

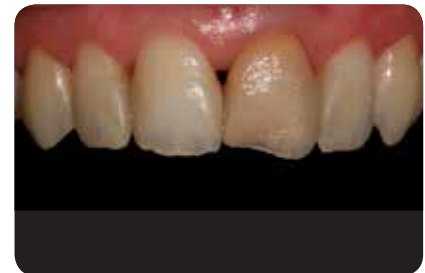

Fig. 3: Pre-op intraoral view

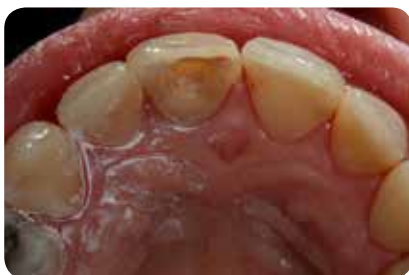

Fig. 4: Prep for inside/ outside whitening

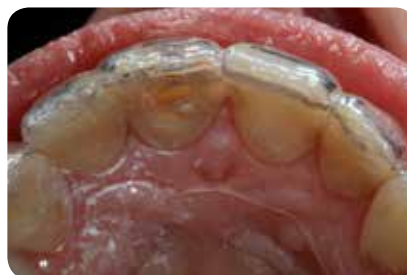

Fig. 5: Essix retainer used for whitening

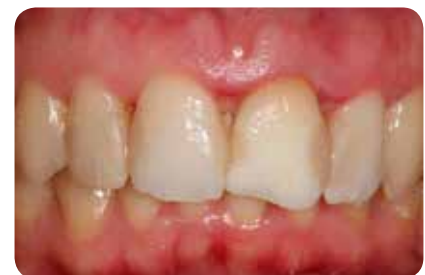

Fig. 6: Inside/ outside whitening post-op

from the teeth, which would otherwise have interfered with the bonding process.

Restoration

For the third phase of the treatment process, the aim was to improve the shape of the central incisors as well as replace the defective Class III composite restorations. This was achieved with a single shade composite, which is both effective and convenient for restorations of this nature. In this instance, BRILLIANT EverGlow shade A1/B1 from COLTENE was chosen, as the universal composite works well as a single shade composite and it doesn't run or stick to instruments, thus allowing for easy modelling of the composite resin. BRILLIANT EverGlow also features a Duo Shade system, which allows the composite to blend in well with the adjacent tooth structure making the restoration look virtually invisible (Fig. 8, 9 and 10). A white opaque tint from the MIRIS 2 range, also by COLTENE, was used to mask discolouration on the cervical area of the upper left central incisor. Free hand incremental build up technique was uti-

lised to restore the central incisors with direct composite resins. To finish, the restorations were polished using a fine diamond followed by alumina impregnated silicone points and fine Sof Lex discs.

Review

As the BRILLIANT EverGlow polishes to a very high lustre and is incredibly durable thanks to its submicron particle filler particle size (Fig. 11), I am pleased with the result of the restoration. As for the orthodontic aspect of the treatment, both central incisors are now proportionate resulting in a more aesthetically pleasing smile. As such, the patient is extremely delighted with the treatment outcome, which she says has "exceeded her expectations" (Fig. 12).

Nadeem Younis is a Principal Dentist at Bridge Dental Practice in Burnley and a full member of the British Academy of Aesthetic Dentistry (BAAD). Here, he presents a smile makeover case using a minimally invasive multidisciplinary approach.

CONTACT

Dr. Nadeem Younis
Bridge Dental Practice
2 Colne Road
Burnley/Lancashire BB10 1LA
United Kingdom
Tel: +44 1282 423973
Email: info@bridgedentalpractice.co.uk
To find out more visit www.coltene.com

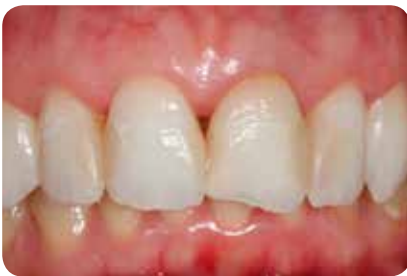


Fig. 7: Upper arch whitening post-op

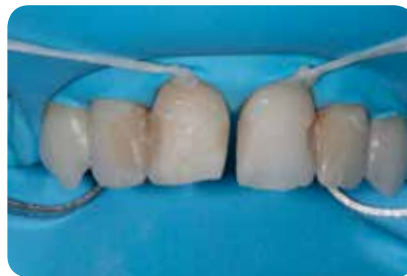

Fig. 8: Preparation of upper central incisors for composite resins

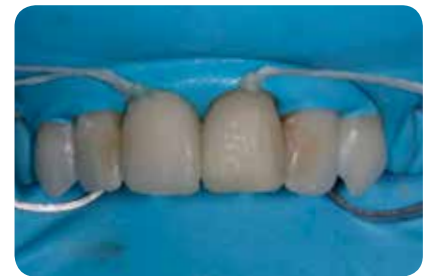

Fig. 9: Composite build up

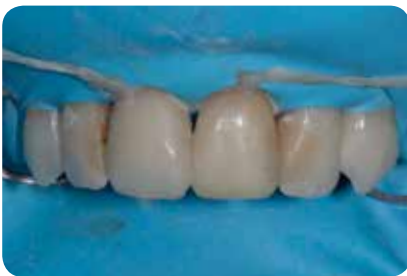

Fig. 10: Polished composites upper centrals

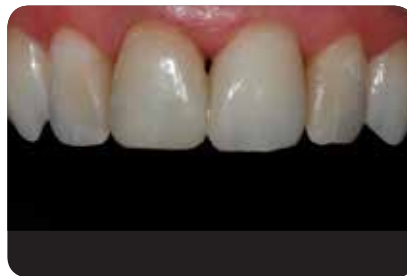

Fig. 11: Post treatment

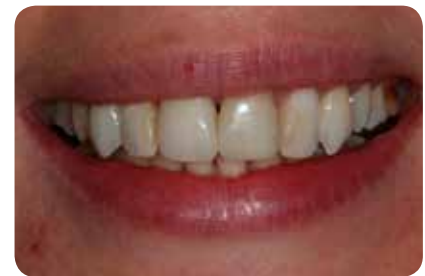

Fig. 12: Final smile