

“Restoring endodontically treated teeth: a simplified technique”

DR. ENRIQUE KOGAN & ALEJANDRO KOGAN B., SEPTEMBER 2009

Restoring endodontically treated teeth is one of the procedures that we regularly see in our dental offices.

This type of situation - which represents a specific issue because the tooth structure is compromised - is currently one of the biggest challenges for the practitioner ⁽¹⁾.

When we find a tooth that has been restored with a post and core/crown, we understand that they are all made from different materials, but at the same time, they should all function as a one unit ⁽²⁾. Teeth restored with flexible fiber posts are at less risk to suffer from root fractures and have also exhibited longer life-spans than those restored with rigid materials ⁽³⁾.

As the deformation of the post closely resembles that of the cement - deflection

to occlusal forces - it will be better at reducing the incidence of root fractures. This is the reason why the mechanical and adhesive properties of the cement are as important as those for posts ⁽⁴⁾.

This long and complex restorative procedure has been reduced to a simplified technique by introducing fiber posts and materials with adhesive-cementation properties that can perform like a core and also like a permanent cement for the final restoration. All-in-one systems for cementing the post, preparing the core and cementing the final restoration, such as ParaCore Automix 5ml Syringe System (Coltène/Whaledent), are excellent options for use with these procedures (Fig. 1).

Clinical case

The patient presented with a coronal

fracture in the buccal, lingual and distal aspects of the first lower-right premolar (Fig. 2).

The first procedures are: a) diagnose and determine if the tooth can be restored, and b) its prognosis. The clinical and radiographic exams will allow us to make the correct decision. In this case, the tooth has already undergone root canal treatment (Fig. 3). The correct treatment is to restore the tooth with a fiber post and crown. The type and size of post will be determined by radiographic analysis, and we will always respect the principles of endodontic sealing. We decided to use the ParaPost Fiber Lux yellow post (Coltène/Whaledent) (1.0mm) (Fig. 4).

Since we will use an adhesive technique, we recommend the use of a rubber dam, since it not only improves the



Fig. 1: ParaCore Automix 5ml Syringe System (Coltène/Whaledent)

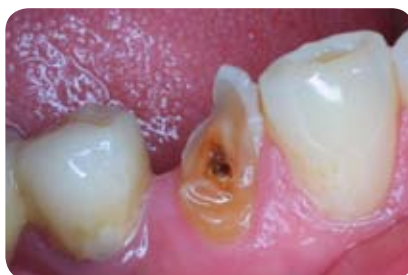

Fig. 2: Preoperative situation

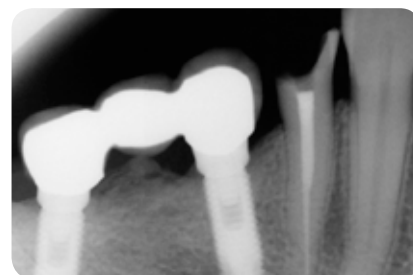


Fig. 3: Radiographic evaluation



Fig. 4: ParaPost Fiber Lux (Coltène/Whaledent)

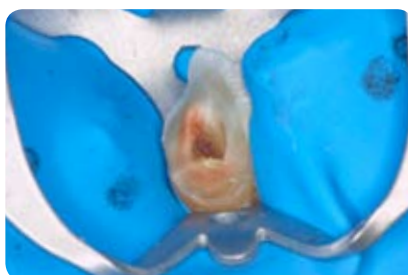

Fig. 5: Isolation using a rubber dam

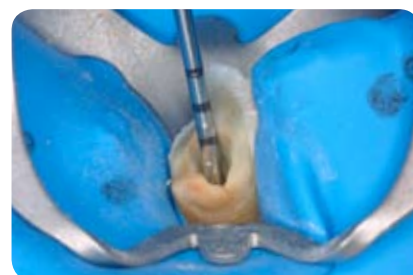


Fig. 6: Preparation of the site for the post

visibility, but also provides a dry and contaminant-free site (Fig. 5).

Immediately after this, we clean and eliminate caries with the indicated drills - depending on the posts to be used - and prepare the site for the ParaPost Fiber Lux post (Coltène/Whaledent) (Fig. 6).

Once the site has been prepared for the post and we have verified that the remaining gutta-percha is in the apical portion, we then place the post into the root canal (Fig. 7) and adjust the length of the post as needed. In this case, we had to reduce the apical length of the post by 1 mm using a diamond bur (Fig. 8).

Now, it is time to prepare the tooth with the ParaBond Non-Rinse Conditioner from the ParaCore Automix 5ml Intro Kit (Coltène/Whaledent) (Fig. 9 and 10). Message it for 30 seconds inside the root canal and on the crown, and dry it using air and paper points to eliminate any residual conditioner (Fig. 11).

Once the root canal has been dried, but not dehydrated, the ParaBond Adhesive from the ParaCore Automix 5ml System (Coltène/Whaledent) should be applied (Fig. 12). Mix equal parts of liquid A+B. To allow better access into the canal, use a mini sponge to apply the mixed components for 30 seconds to all previously prepared structures (Fig. 13).

The next step is to thin down the adhesive with air to eliminate the solvent before light curing for 20 seconds (Fig. 14). Now we are ready to cement the post by injecting the ParaCore Automix 5ml cement into the canal (Fig. 15) using an endodontic tip and placing the post in the correct position. We then remove any excess and light cure for the final 20 seconds (Fig. 16, 17 and 18).

Following this, we proceed by rebuilding the core immediately and syringe the ParaCore Automix 5ml cement (Coltène/Whaledent) into the ParaForm (Coltène/Whaledent) matrix for cores. This

will form the preliminary shape of the core. It is then placed on the tooth and light-cured again for 40 seconds (Fig. 19, 20 and 21).

We can then proceed with preparing the core (Fig. 22), taking the impression and evaluating with x rays (Fig. 23).

Once the final restoration has been verified and adjusted, we can cement it using the same ParaCore Automix 5ml cement (Coltène/Whaledent). We had previously used ParaBond Non-Rinse Conditioner (Coltène/Whaledent) for 30 seconds (Fig. 24), and after drying we had placed the Adhesive ParaBond A+B (Coltène/Whaledent) for 30 seconds (Fig. 25). At this point, we can cement the restoration permanently by light curing for 20 seconds (Fig. 26) to create one homogenous unit comprising the fiber post, core, permanent cement and crown.

Thanks to the advances of this all-in-one system, we can now cement the fiber

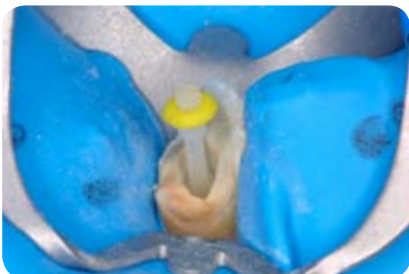


Fig. 7: Trial seating of the ParaPost Fiber Lux post (Coltène/Whaledent)



Fig. 8: Adjusting the length of the post



Fig. 9: ParaBond Non-Rinse Conditioner

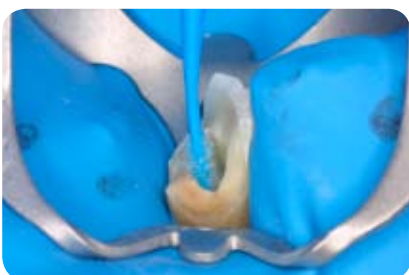


Fig. 10: Placement of the ParaBond Non-Rinse Conditioner (Coltène/Whaledent)

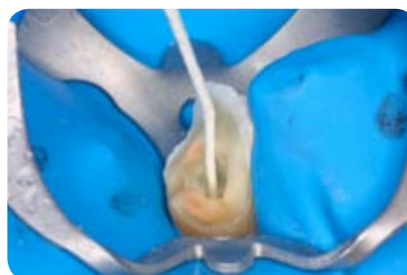


Fig. 11: Removal of the residual conditioner



Fig. 12: ParaBond Adhesive (Coltène/Whaledent)

post with the same material that was used for building up the core and cementing the final restoration. The good prognosis that we had been looking for is now reality. The bonding and adhesion seen under a scanning electron microscope proves it (Fig. 27 and 28).

CONTACT

Dr. Enrique Kogan F.
Palmas 830-101
México D.F. 11000
ekoganf@gmail.com
(5255) 5540 0919

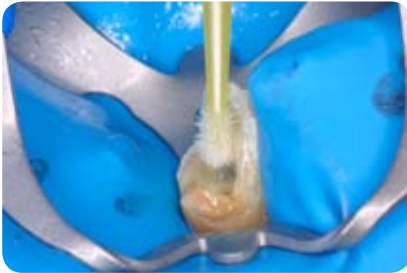


Fig. 13: Placement of the ParaBond Adhesive (Coltène/Whaledent)

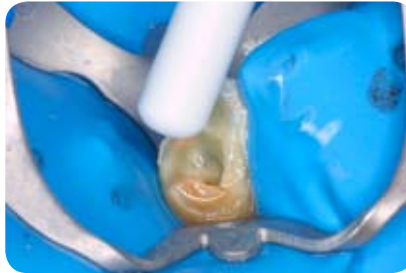


Fig. 14: Thinning down the adhesive



Fig. 15: ParaCore Automix 5ml cement (Coltène/Whaledent)

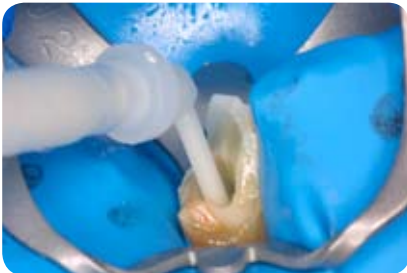


Fig. 16: Injection of the ParaCore cement (Coltène/Whaledent)

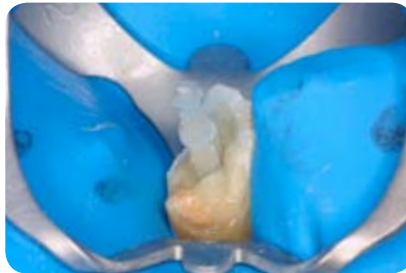


Fig. 17: Placement of the post

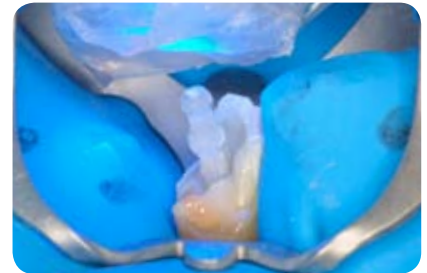


Fig. 18: Light curing the cement

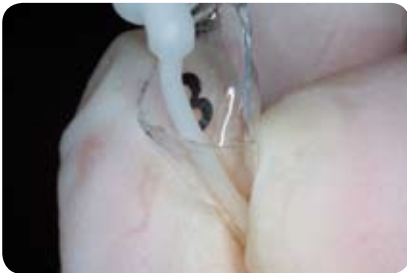


Fig. 19: Placement of the ParaCore cement (Coltène/Whaledent) in the ParaForm Coreformer matrix

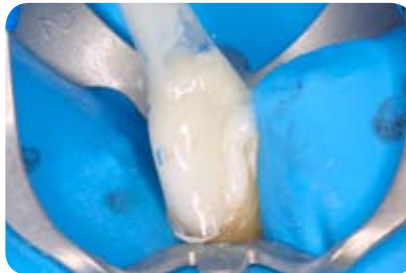


Fig. 20: Matrix in place

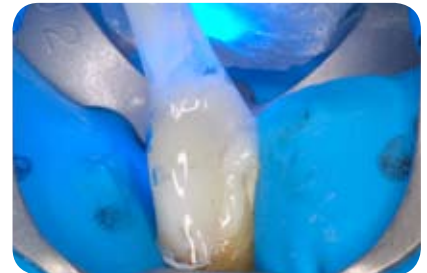

Fig. 21: Light curing the core

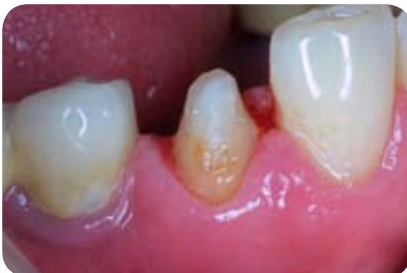

Fig. 22: Final preparation

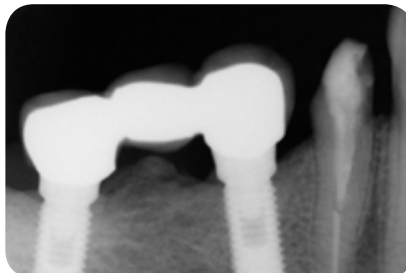


Fig. 23: Evaluation with X-rays

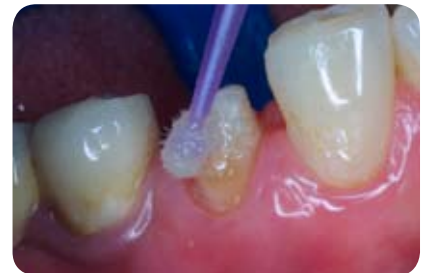

Fig. 24: Placement of the ParaBond Non-Rinse Conditioner

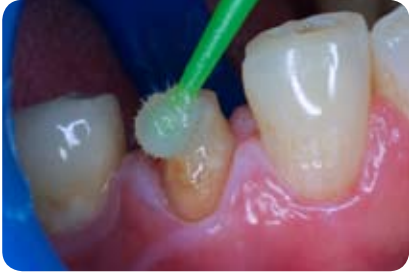

Fig. 25: Placement of the ParaBond Adhesive

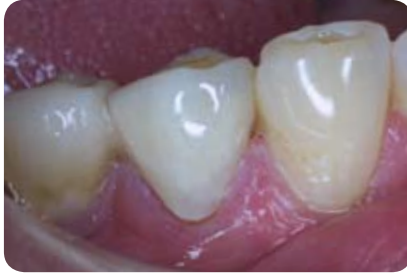

Fig. 26: Final restoration





Fig. 27 and 28: Scanning electron microscope images showing the fiber Post cemented with ParaCore Automix 5ml cement (Coltène/Wha-



ledent). Photos are the courtesy of Dr. Enrique Kogan and Dr. Rodrigo Arias.

Conclusions

As this technique is highly simplified, the probability of errors occurring is much lower: The ParaCore Automix 5ml all-in-one system (Coltène/Whaledent) provides us with an alternative that is fast and efficient for restoring teeth which have undergone endodontic treatment.

¹ Geirsson J., Sigurdsson.- Posts in Endodontically Treated Teeth. J Esthe. And Rest. Dent. Sep-Oct. 2003.

² Pitel M., Hicks N.- Evolving technology in endodontic posts. Comp. of Cont. Educ. in Dent. January 2003.

³ Mannocci F., Ferrari M., Watson T.- Intermittent Loading of teeth restored using quartz fiber, carbon -quartz fiber and zirconium dioxide ceramic root canal posts. J. Adhes Dent. Jan 1999.

⁴ Baldissara P.- Mechanical Properties and in Vitro Evaluation (Chapter 5) . In Ferrari M., Scotti R.- Fiber Posts. Characteristics and Clinical Applications. Masson. 2002.