

Rehabilitation of the anterior maxilla with BRILLIANT EverGlow

DR. MED.DENT. MARKUS LENHARD
SEPTEMBER 2016

COLTENE is offering a modified shade concept using "dual shades" (Duo Shades). In other words, the shades available are created to simultaneously replicate two shades of the VITA classic shade guide.

As a consequence, the number of shades in the set is reduced considerably, intending to simplify shade selection for the operator and saving on storage space. Overall, there are seven universal shades available, as well as two translucent and three opaque shades, already including three bright shades for bleached teeth.

The translucency of the universal shades has been designed to fall between dentine and enamel to allow successful restoration of anterior teeth with a single shade or layer. In principle, there is the option of customising a layer by using opaque and translucent material. Then again, creating mammelons and very translucent incisal edges tends to be the exception and therefore is a niche in high-end aesthetics, which is usually not demanded by patients.

It therefore is generally desirable to be

able to restore the majority of cases with so-called universal shades, which do not require a separate layering of dentine and enamel shades.

The case at hand involves rehabilitation of the anterior maxilla and restoration of cuspid guidance with laterotrusion in the worn dentition.

The 38-year old male patient wished for aesthetic improvement to his anterior teeth in the maxilla (Fig. 1). A check of functional occlusion showed loss of cuspid guidance in laterotrusion in favour of the posterior and anterior dentition (Figs. 2 and 3). Due to attrition, the anterior teeth demonstrated significant loss of vertical dimension. Loss of OVD in the posterior region through abrasion was minimal, making it unnecessary to plan to increase OVD. Therefore, treatment could be limited to the functional and aesthetic correction of the anterior region.

The shade selected using the bespoke BRILLIANT EverGlow shade guide was directly applied to the incisal edge of one

of the two central incisors without etching and bonding and then light cured. Duo Shade A3/D3 was chosen for this case. This technique for shade selection is very reliable as both hue and translucency can be assessed. Above all, it is crucial that the relevant tooth is not dried beforehand, as this leads to a change in colour of the tooth. The tooth will only return very slowly to its original colour after renewed water absorption. Furthermore, the composite must be polymerised for an adequate shade comparison, as the colour tone changes during polymerisation due to depletion of the photoinitiator and the crosslinking of the monomers changing the refractory index of the organic matrix. This means that shade and translucency can only be replicated by polymerised composite. After shade selection the applied composite was removed with a scaler.

Firstly, cuspid guidance was restored on both sides. Only minimal bevelling was generally carried out to prepare and the transition from the vestibular surfaces to incisal was designed convex using Sof-

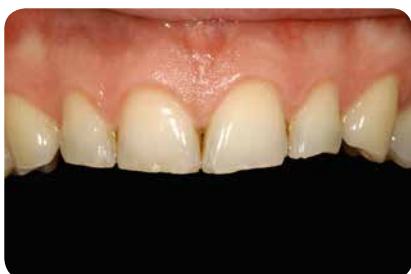

Fig. 1: Initial situation: abraded maxillary anterior with small enamel chipping at the incisal edges of the incisors.

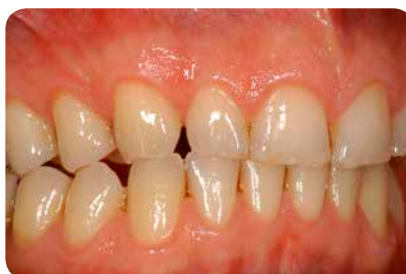

Fig. 2: Laterotrusion to the right: loss of cuspid guidance at laterotrusion in favour of lateral and anterior grouping.

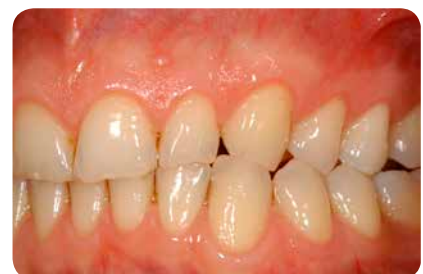

Fig. 3: The situation on the left side corresponds accordingly.

Lex discs (Lenhard 2004). After selective etching of the enamel for 30s, ONE COAT 7 UNIVERSAL was applied (Figs. 4 and 5). The cuspids were each restored with only one layer of BRILLIANT EverGlow A3/D3 (Fig. 6). This design has no effect on occlusion, but leads to cuspid guidance at laterotrusion.

To restore cuspid guidance it is usually sufficient to just restore the abrasion facets on the upper cuspids (Figs. 7 and 8). However, should interference with the anterior mandible occur again after build-up of the incisors at laterotrusion, then the abrasion facets of the lower

cuspids need to be corrected as well.

The technically simple correction of the cuspids is, as a rule, performed with a relatively dry field, so that cuspid guidance can be checked immediately. A completely dry field with use of rubber dam is recommended for the build-up of the incisors, as this facilitates and accelerates implementation of the build-ups (Fig. 9).

To assess the incisal line for corrections of the maxillary anterior, the entire anterior from cuspid to cuspid needs to be isolated as a matter of principle. The rubber dam

is affixed to the first premolars, whereby the dam can simply be placed over the clamps (Fig.10). Following etching and application of adhesive, the anterior teeth were built up stepwise with Duo Shade A3/D3 (Figs. 11-15). Whereas certain overall layer thicknesses need to be taken into account in terms of aesthetic success when layering with opaque, dentine, enamel and translucent materials, the single shade approach allows to cover the entire restoration with one single universal shade. This simplifies the process considerably. To avoid palatal excess, the finger can be used as a "matrix". However,

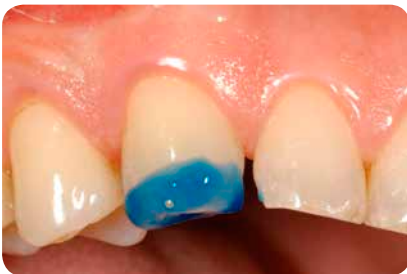

Fig. 4: Selective enamel etching for 30s with 35% phosphoric acid (Etchant Gel S, COLTENE).

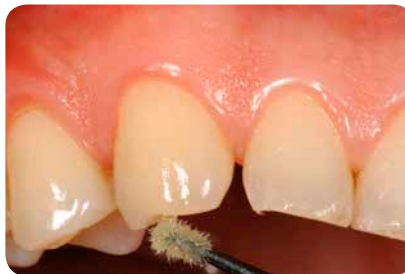

Fig. 5: Establishing a hybrid layer is to be supported actively by massaging for 20s with ONE COAT 7 UNIVERSAL.

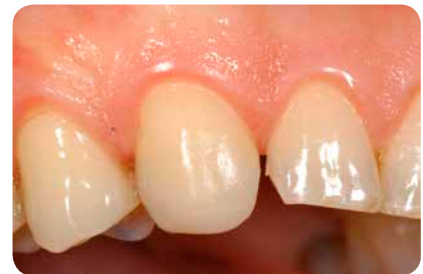

Fig. 6: Situation after build-up of the cuspid with a single layer of BRILLIANT EverGlow A3/D3.

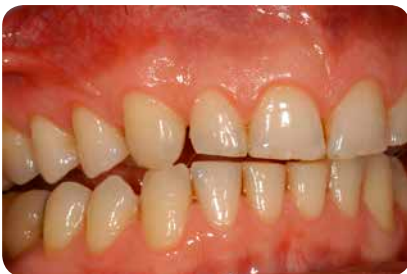

Fig. 7: Restored cuspid guidance results in the desired disclusion of all other teeth at laterotrusion motion.

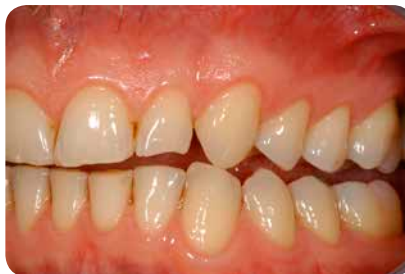

Fig. 8: Situation after restoring cuspid guidance on the left side.

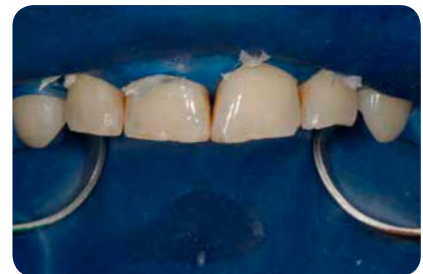

Fig. 9: For build-ups in the anterior tooth region, isolation should always embrace the entire anterior front.

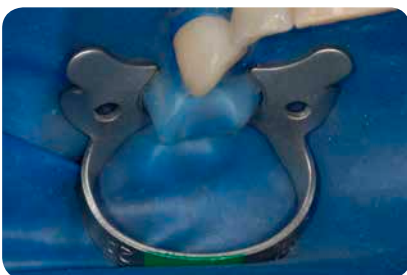


Fig. 10: The rubber dam is secured on the premolars (clamp 2A HYGENIC Fiesta) without the need for punching an additional hole.

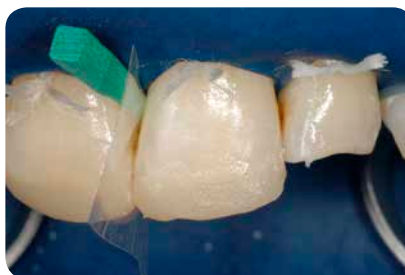

Fig. 11: As only one shade is used, there is no need for elaborate layering.

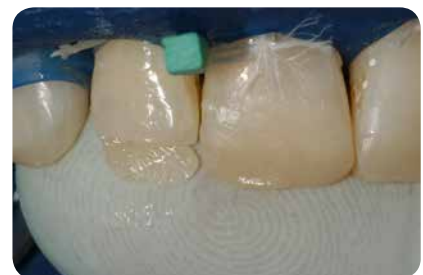

Fig. 12: To avoid palatal excess, the finger can be used as "matrix".

one should note that dental monomers can also penetrate latex and nitrile gloves and possess a certain allergenic potential. Penetration of the monomers through the gloves is, however, not so immediate that it is sufficient to change the glove after build-up of the palatal area (Aalto-Korte et al. 2007, Goon et al 2006, Nakamura et al. 2003, Lönnroth et al. 2003) (Fig.12).

After gross finishing, the rubber dam was removed and the final shape of the teeth (length and angle characteristic) determined with grinding discs and finishing strips. This was followed by

polishing with DIATECH Shape- Guard polishers (Fig. 16). Finally, laterotrusion was checked again (Fig. 17). However, restoration of the abrasion facets of the lower cuspids could prove useful to provide additional protection to the anterior tooth restorations in the maxilla.

Figure 18 shows the immediate postoperative state. One can clearly see the transition of the teeth to the composite build-ups. The restorations appear too translucent and too dark. This postoperative appearance is still desirable by all means. The hard tooth substance dries during treatment, the teeth thus

become significantly more opaque and brighter. Renewed water absorption occurs postoperatively through diffusion with saliva and drains relatively slowly. Even with permanent wetting with saliva or water, it takes about one hour until the original colour of the teeth is restored. This means that aesthetically successful restorations must always appear too translucent and too dark in the immediate postoperative situation.

One week later the patient presented again for a follow-up and for assessment of the aesthetic integration of the restorations (Figs. 19 and 20). The restorations

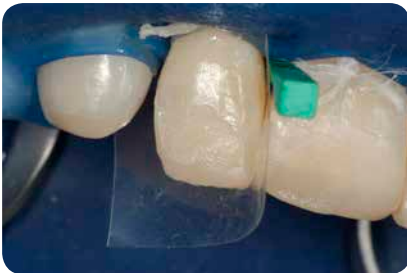

Fig. 13: A translucent matrix is placed for layering the approximal wall.

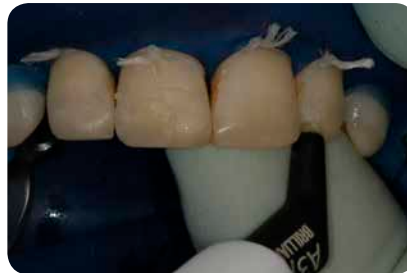

Fig. 14: Universal shade A3/D3 is used exclusively for the restoration.

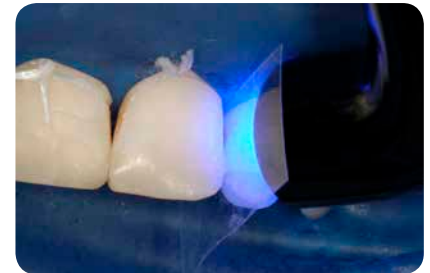

Fig. 15: The respective layers were cured with an S.P.E.C. 3 LEDs with 11 mm light guides at 1600 mW for 15 s. each.

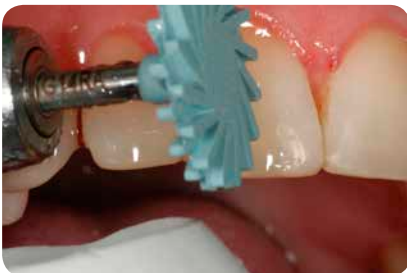

Fig. 16: Polish with DIATECH Shape- Guard polishers.

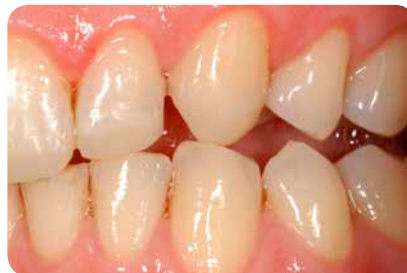

Fig. 17: The final check of cuspid guidance only shows anterior contacts at laterotrusion on imposition of the lower incisor.

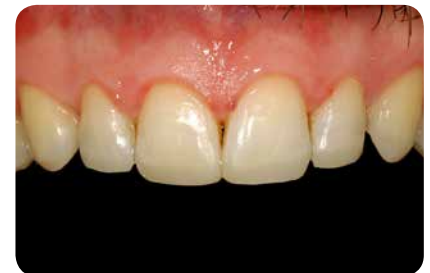

Fig. 18: Immediate postoperative final situation. The restorations appear too dark and too translucent when compared with the dried hard tooth substance.

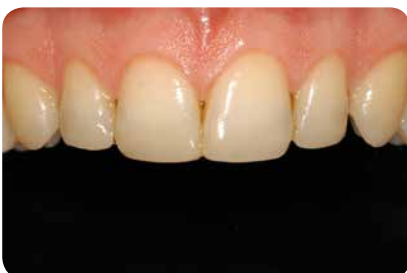

Fig. 19: Excellent optical integration of the restorations was evident postoperatively after one week.

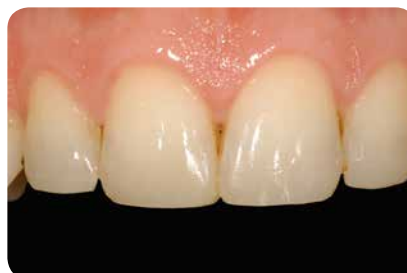

Fig. 20: The middle incisors one week post-operatively, the build-ups appear natural.

demonstrated excellent colour matching and the transitions from hard tooth substance to restoration were hardly noticeable, even under magnification.

In conclusion, it can be said that the case presented here with BRILLIANT EverGlow allowed an extremely user-friendly, fast and very good aesthetic rehabilitation of the maxillary anterior by only using a single universal shade. Elaborate layering with opaque and translucent materials can thus presumably be limited to a minority of cases which present with pronounced incisor characteristics.

CONTACT

Dr. Markus Lenhard
Bahnhofstrasse 29
8259 Etwilen/Switzerland
markus.lenhard@bluewin.ch



Literature

Aalto-Korte K, Alanko K, Kuuliala O, Jolanki R (2007). Methacrylate and acrylate allergy in dental personnel. *Contact Dermatitis* 57(5):324-30.

Goon AT, Isaksson M, Zimerson E, Goh CL, Bruze M (2006). Contact allergy to (meth)acrylates in the dental series in southern Sweden: simultaneous positive patch test reaction patterns and possible screening allergens. *Contact Dermatitis* 55(4):219-26.

Lenhard M (2004). Ästhetische Frontzahnrestorationen mit Komposit. *Quintessenz* 55(9): 961-976.

Lönnroth EC, Eystein Ruyter I (2003). Resistance of medical gloves to permeation by methyl methacrylate (MMA), ethylene glycol dimethacrylate (EGDMA), and 1,4-butanediol dimethacrylate (1,4-BDMA). *Int J Occup Saf Ergon* 9(3):289-99.

Nakamura M1, Oshima H, Hashimoto Y (2003). Monomer permeability of disposable dental gloves. *J Prosthet Dent* 90(1):81-5.

Wallenhammar LM, Ortengren U, Andreasson H, Barregård L, Björkner B, Karlsson S, Wrangsjö K, Meding B (2000). Contact allergy and hand eczema in Swedish dentists. *Contact Dermatitis* 43(4):192-9.